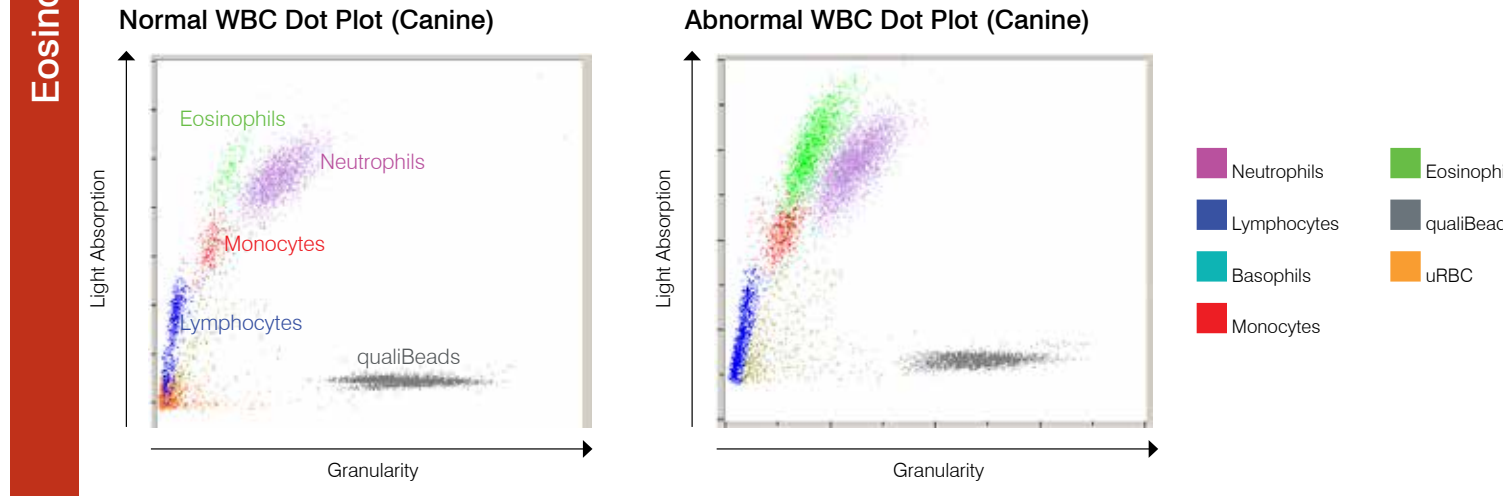
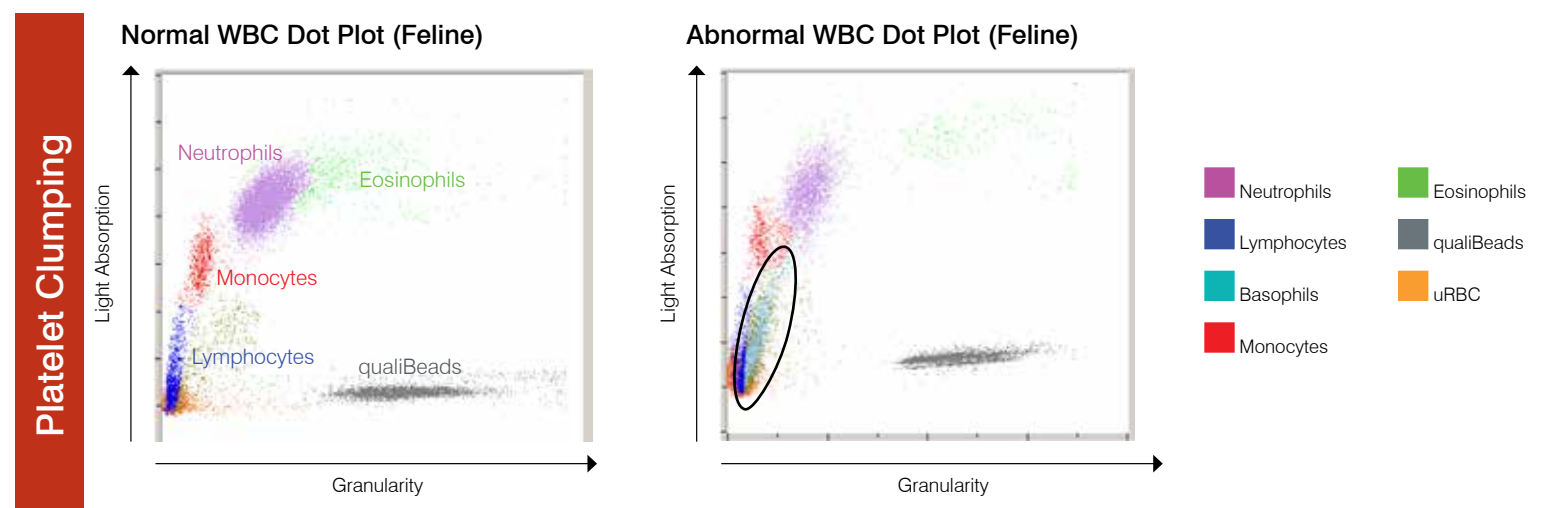
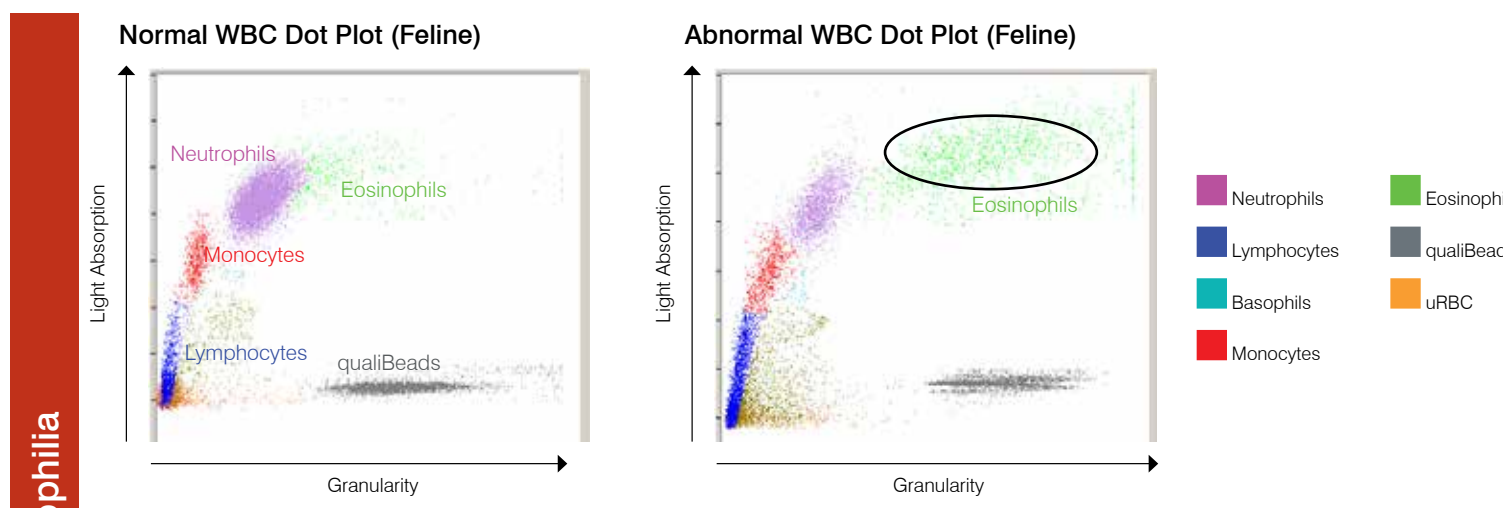
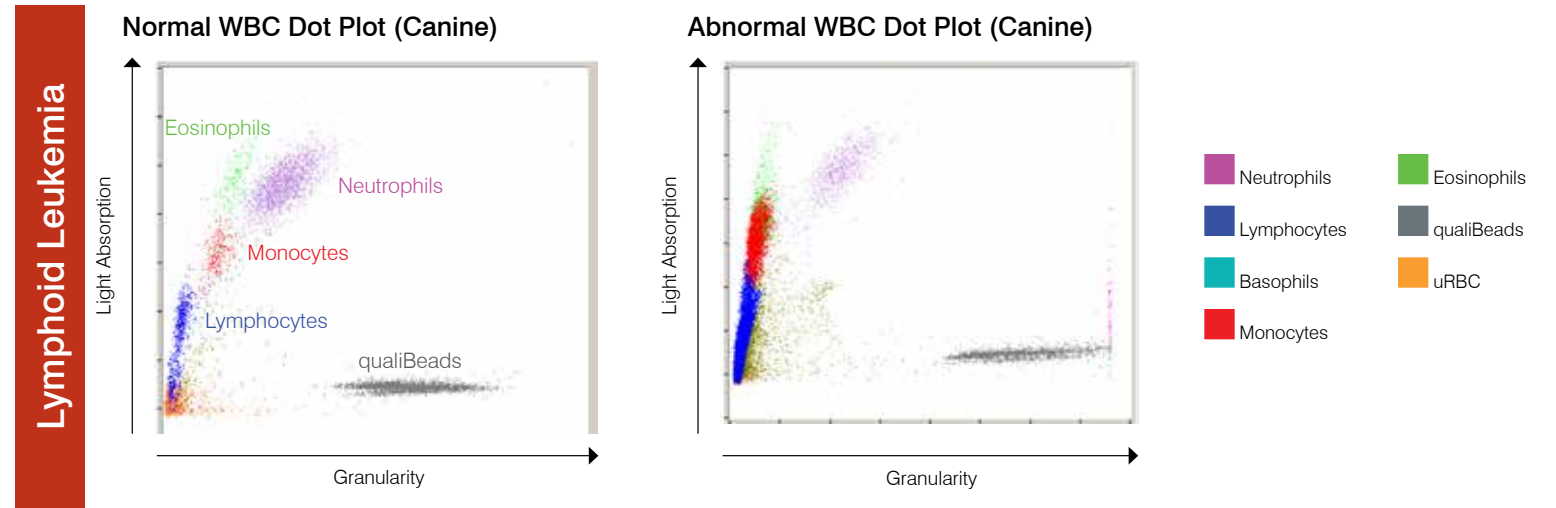
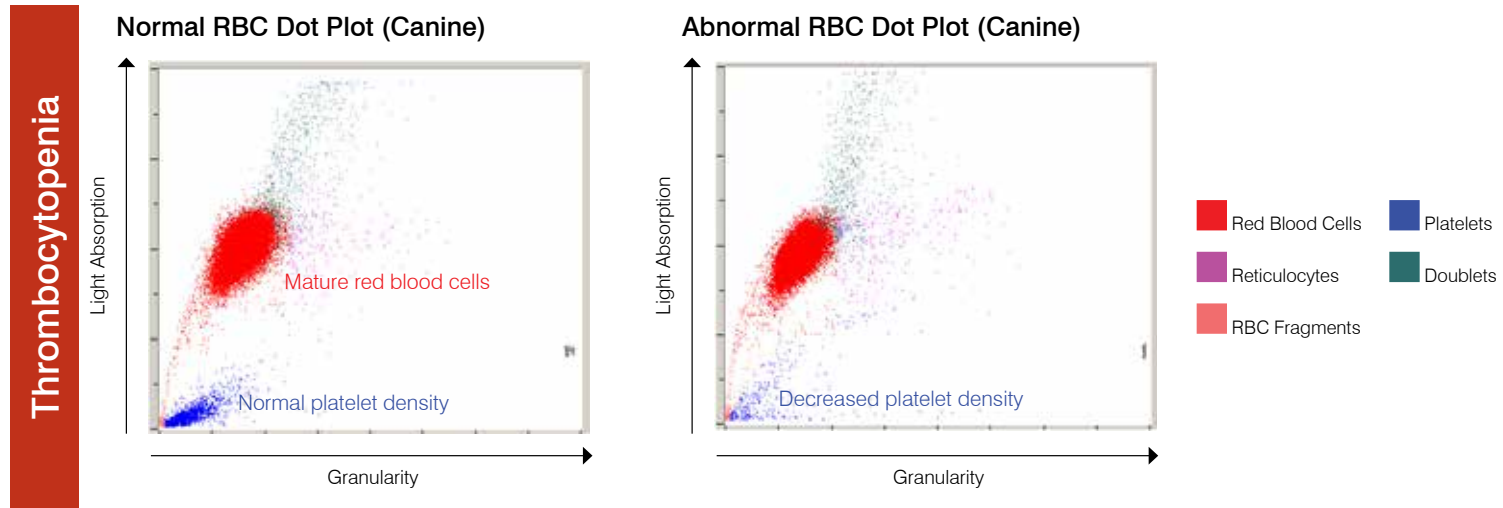
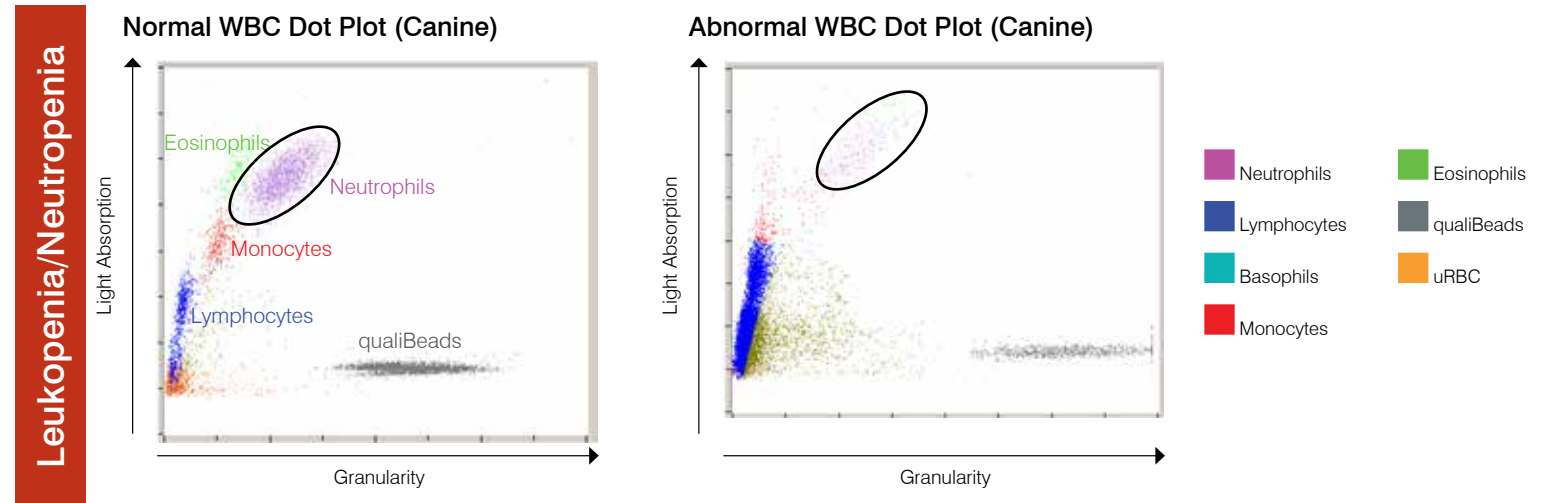
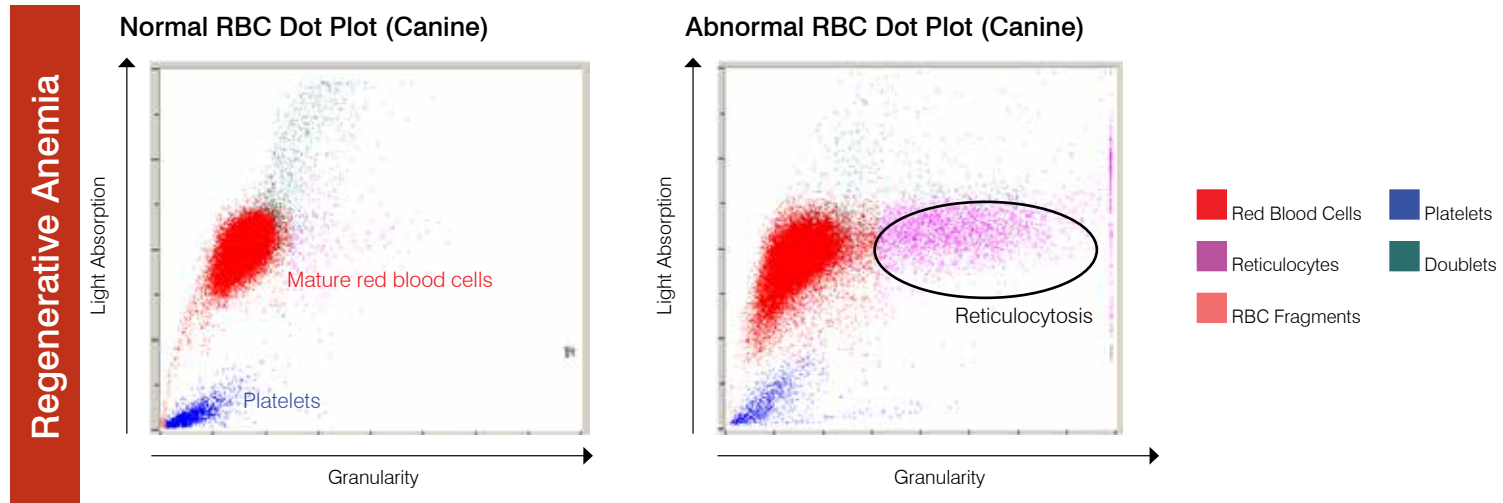


# Interpreting IDEXX LaserCyte\* Dx/IDEXX LaserCyte\* Hematology Analyzer Dot Plots

Dot plots are a visual representation of the complete blood count. They are beneficial for quickly interpreting and verifying results. This poster will help you identify various diseases on feline or canine dot plots generated from the LaserCyte Dx/LaserCyte analyzer.



**For more information about LaserCyte dot plots, contact IDEXX Customer and Technical Support.**

IDEXX Customer and Technical Support	
U.S./Canada 1-800-248-2483	New Zealand 0800 83 85 22
Europe idexx.eu	China 400-678-6682
Netherlands 31 (0)70 700 7033	South Korea 080 7979 133
Australia 1300 44 33 99	Taiwan 0800 291 018
	Japan 0120-71-492

## Regenerative Anemia

Reticulocytosis (an increased number of reticulocytes) is the hallmark and most objective indicator of a bone marrow response. It is most commonly used to accurately identify a regenerative anemia but may also be seen with a variety of other conditions, including partial and complete compensated hemolytic disease. Reticulocytes are easily identified as the magenta dots to the right of the red blood cell population (red dots). The new methylene blue stain in the CBC5R tubes precipitates the residual reticulum in these immature red blood cells, which gives these cells increased granularity and therefore the shift to the right. In the normal dot plot, there are dramatically reduced numbers of the reticulocytes, noted as a decreased density of magenta dots, when compared to the patients with significant increases in reticulocyte numbers. Rapid review of the dot plot allows quick validation of the reticulocyte count and therefore confidence in results generated.

## Thrombocytopenia

Thrombocytopenia can be a critical finding in a CBC, and rapid validation of results from the hematology analyzer is essential. In the red blood cell and platelet dot plot, severe thrombocytopenia is easily validated. In the normal patient dot plot, there are dense accumulations of blue dots that represent individual platelet optical profiles. During severe thrombocytopenia, the density of the blue dots is dramatically reduced compared to normal. Because platelet clumping or partial sample clotting may interfere with the recognition of platelets by the analyzer and they may not appear on the dot plot, rapid microscopic evaluation of a blood film in any case of reported decreased platelet counts is warranted. This is true for all hematology analyzers used for in-house testing as well as commercial and academic reference laboratories.

## Eosinophilia

Recognition of increases in eosinophils (eosinophilia) is an important observation that directs diagnostic investigations towards specific diseases, such as allergies, parasites, and many others. Because they are of such value, rapid validation of reported eosinophilia is quite important. In the dot plots, eosinophils (green) are located to the left of the neutrophils in the dog and to the right of the neutrophils in the cat. Different patterns are seen for different species because of their somewhat unique morphologic features. In the cases where a significant eosinophilia is reported, the increased density of the eosinophil dot clouds make the rapid confirmation of increased numbers of these cells simple.

## Leukopenia/Neutropenia

Leukopenia or a decrease in total leukocyte numbers and, in particular, neutropenia or decreased in neutrophil numbers often have high clinical significance related to overwhelming inflammatory disease and possible effects of chemotherapy—immediate knowledge of these situations is critical to the veterinarian. Marked decreases in leukocytes can be rapidly validated by examining the WBC dot plot. When an isolated cell type such as the neutrophil is significantly decreased, it is easily recognized because of the obvious lack of or dramatic decrease in density of the dot plot cloud associated with that particular leukocyte. In these cases, there is a leukopenia characterized by a marked neutropenia; note the absence of the cloud of purple dots that represent individual neutrophils in the sample.

## Lymphoid Leukemia

Leukemia has multiple presentations; one of the most common is lymphoid leukemia either as a result of progression of malignant lymphoma or primary lymphoid leukemia originating in the bone marrow. Most advanced hematology analyzers cannot accurately characterize these circulating malignant cells. In many cases, the analyzers attempt cellular characterization, but because of difficulty in differentiating the different types of leukocytes, an **Abnormal WBC Distribution** message is reported to assure that there is follow-up evaluation of a blood film or submission to a reference laboratory for validation of the analyzers attempts. In the normal WBC dot plots, there are distinctly identified clouds of different colored dots that represent the different populations of leukocytes typically seen in the peripheral blood. However, in the dot plots from the lymphoid leukemia patients, clear distinction between the different leukocyte clouds is not present; there is a continuum between different colored clouds. In these cases, including the appropriate message code indicating that the analyzer had difficulty in making an accurate leukocyte characterization along with a blood film or EDTA sample submission to the reference laboratory is recommended.

## Platelet Clumping

Platelet clumping is a common problem in veterinary medicine, especially with feline samples. Any time there is difficulty in sample collection resulting in a delay in placing sample into the EDTA tube or delay in proper mixing, there is a potential for platelet clumping. There are different degrees of platelet clumping, and most advanced analyzers have the capability of recognizing large platelet clumps. When identified, an appropriate message is relayed to the operator along with qualification of selected results that could be impacted by the platelet clumping. The analyzer may still provide values; however, if there are qualifiers relayed or message codes reported, further evaluation and confirmation of the reported values is essential. A rapid review of the dot plots can also provide the operator with very quick validation that large platelet clumps are present. Platelet clumps will be recognized as a linear cloud of dots almost parallel to the lymphocyte/monocyte populations. A rapid blood film review can allow timely recognition of large platelet clumps and verification of results reported. If platelet clumps are reported or observed on the blood film, collection of a new sample for analysis is recommended.

